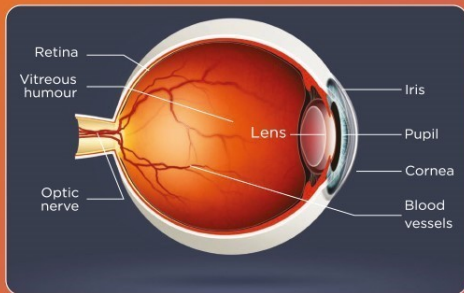


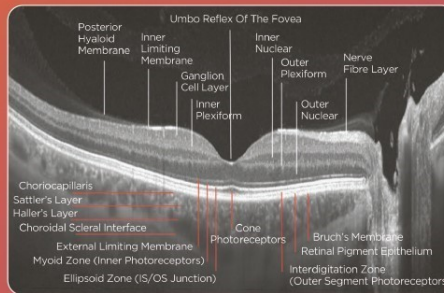
OPTISCHE KOHÄRENZ TOMOGRAPHIE

Das neue Level der OCT-Bildgebung

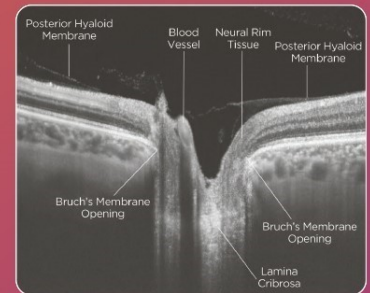
DAS AUGE



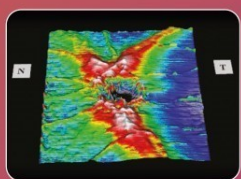
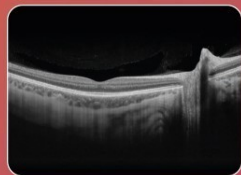
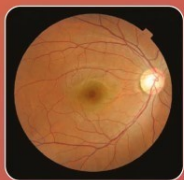NETZHAUTSCHICHTEN



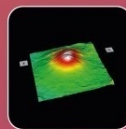
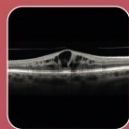
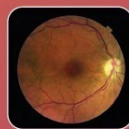SEHNERV



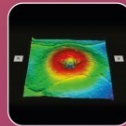
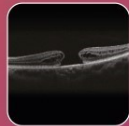
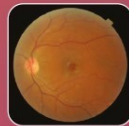GESUNDE NETZHAUT



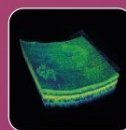
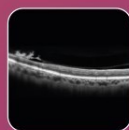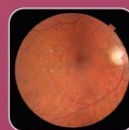DIABETISCHES MAKULAOEDEM



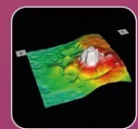
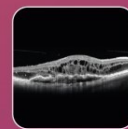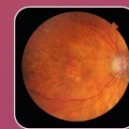MAKULALOCH



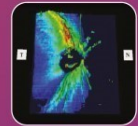
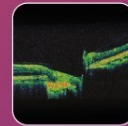
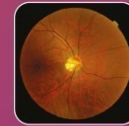DIABETISCHE BLUTGEFÄßE



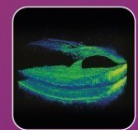
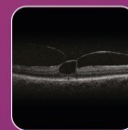
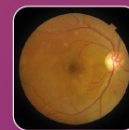ALTERSBEDINGTE MAKULADEGENERATION




GLAUKOM



VITREOMAKULÄRE TRAKTION



SIMULIERTES SEHVERMÖGEN



Beispielbilder zur Verfügung gestellt vom National Eye Institute (Bethesda, MD)

VEREINBAREN SIE IHRE OCT-UNTERSUCHUNG!

TOPCON Healthcare